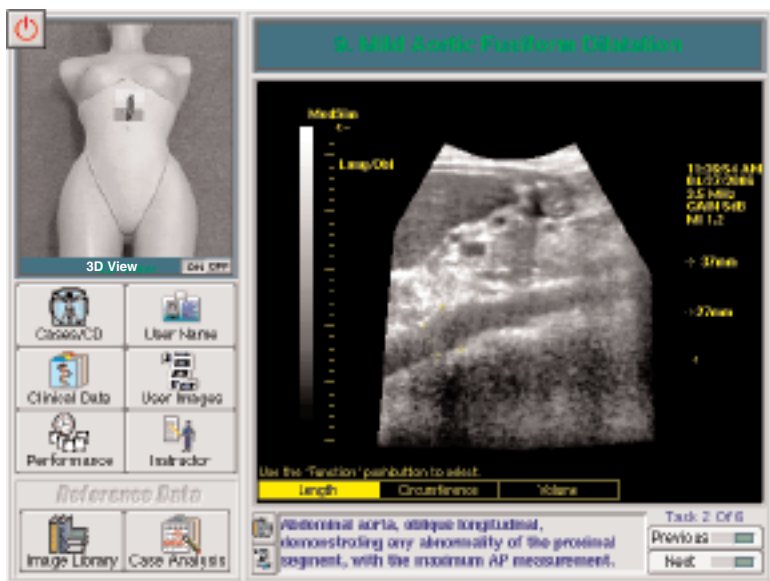


Full Screen Image Showing User Interface and Mild Aortic Fusiform Dilatation



MODULE 4 - ABDOMINAL AORTA

Abdominal Aorta - is the fourth Module in the Emergency Medicine Series.

This 1 CD Module is comprised of 11 cases.

To familiarize the user with normal midline anatomy, the collection begins with examples of abdominal aorta and its main branches.

In a few combined cases where the aorta is partially obscured by bowel gas, repositioning the patient and using different approaches (anterior, midline, right coronal or left coronal) allows for better visualization of the aorta.

Included in this CD are cases of aortic aneurysm with circumferential mural thrombus, as well as mild aortic fusiform dilatation, atherosclerotic aorta and dilated tortuous aorta.

In all cases the anterior/posterior measurement of aortic diameter is obtained in both longitudinal and transverse planes.

Case material contains tasks with corresponding image references, annotations, clinical data and sonographic summaries.

Abdominal Aorta CD



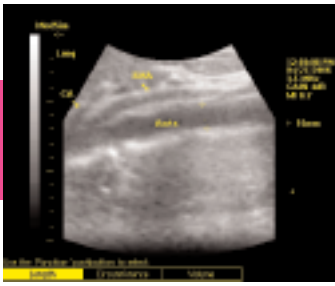
Requires Mock Curved Transducer



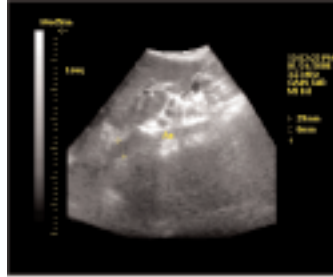
Requires Full Torso Mannequin



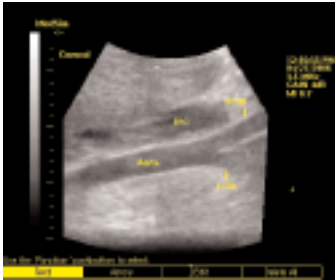EMERGENCY MEDICINE SERIES



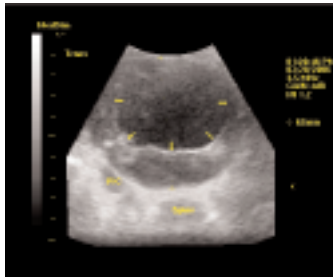
Normal Aorta & Main Branches
in Longitudinal View



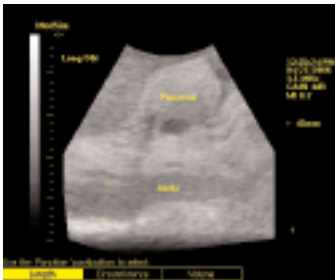Aorta Partially Obscured by
Bowel Gas



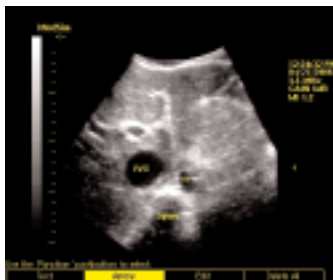Coronal View of Aorta
with Bifurcation



Aortic Aneurysm with
Circumferential Thrombus



Dilated Tortuous Aorta



Aortic Plaque in Transverse View

MODULE 4 - ABDOMINAL AORTA

Examples of available cases:

- Aorta to the Bifurcation
- Right Coronal View of Aorta
- Aorta Partially Obscured by Gas in LPO
- Large Abdominal Aortic Aneurysm
- Atherosclerotic Aorta
- Mild Aortic Fusiform Dilatation
- Left Coronal View of Aorta
- Aorta with Echogenic Material; DIC